

Definitive Evidence for an Autosomal Recessive Form of Hypohidrotic Ectodermal Dysplasia Clinically Indistinguishable from the More Common X-Linked Disorder

F. Munoz,¹ G. Lestringant,² V. Sybert,³ M. Frydman,⁴ A. Alswaini,² P. M. Frossard,² R. Jorgenson,⁵ and J. Zonana¹

¹Department of Molecular and Medical Genetics, Oregon Health Sciences University, Portland; ²Ministry of Health, Abu Dhabi, United Arab Emirates; ³University of Washington and Childrens Hospital Medical Center, Seattle; ⁴Institute of Human Genetics, Tel-Hashomer, Israel; and ⁵South Texas Genetic Center, San Antonio

Summary

A crucial issue in genetic counseling is the recognition of nonallelic genetic heterogeneity. Hypohidrotic (anhidrotic) ectodermal dysplasia (HED), a genetic disorder characterized by defective development of hair, teeth, and eccrine sweat glands, is usually inherited as an X-linked recessive trait mapped to the X-linked ectodermal dysplasia locus, *EDA*, at Xq12-q13.1. The existence of an autosomal recessive form of the disorder had been proposed but subsequently had been challenged by the hypothesis that the phenotype of severely affected daughters born to unaffected mothers in these rare families may be due to marked skewing of X inactivation. Five families with possible autosomal recessive HED have been identified, on the basis of the presence of severely affected females and unaffected parents in single sibships and in highly consanguineous families with multiple affected family members. The disorder was excluded from the *EDA* locus by the lack of its cosegregation with polymorphic markers flanking the *EDA* locus in three of five families. No mutations of the *EDA* gene were detected by SSCP analysis in the two families not excluded by haplotype analysis. The appearance of affected males and females in autosomal recessive HED was clinically indistinguishable from that seen in males with X-linked HED. The findings of equally affected males and females in single sibships, as well as the presence of consanguinity, support an autosomal recessive mode of inheritance. The fact that phenotypically identical types of HED can be caused by mutations at both X-linked and autosomal loci is analogous to the situation in the mouse, where indistinguishable phenotypes are produced by mutations at both X-linked (*Tabby*) and autosomal loci (*crinkled* and *downless*).

Introduction

A critical issue in genetic counseling is the recognition of nonallelic genetic heterogeneity for a disorder. It is especially important if the nonallelic disorders are phenotypically indistinguishable and have differing modes of inheritance. Hypohidrotic (anhidrotic) ectodermal dysplasia (HED), a genetic disorder characterized by abnormal morphogenesis of hair, teeth, and eccrine sweat glands, is usually inherited as an X-linked recessive trait (Clarke et al. 1987). *EDA*, the locus for the X-linked disorder, has been mapped to Xq12-q13.1, and no significant nonallelic genetic heterogeneity have been detected in families with two or more affected generations (Zonana et al. 1992; Zonana 1993). A candidate gene has been identified; however, currently mutations are detectable in only 10% of families (Ferguson et al. 1996; Kere et al. 1996). Males are fully affected with the disorder; however, another one-third of carrier females show no sign of the disorder, one-third have minimal findings (missing a few teeth), and a final one-third have clinically significant involvement, but to a lesser degree than that in an affected male (Freire-Maia and Pinheiro 1982).

Females with balanced X; autosome translocations and Xq12-q13.1 breakpoints (Turleau et al. 1989; MacDermot and Hulten 1990; Limon et al. 1991; Plougastel et al. 1992) have been observed to be affected to the same degree as are males with HED. In 1966, Passarge et al. reported an affected consanguineous sibship with fully affected males and females and no other affected family members (Passarge et al. 1966). Evidence from this family and others suggested the existence of an autosomal recessive form of HED (ARHED) (Parant et al. 1969; Gorlin et al. 1970; Anton-Lamprecht et al. 1988; Kiss and Torok 1990); however, the existence of a separate autosomal recessive form of the disorder has been uncertain, on the basis of the hypothesis that the phenotype of severely affected daughters with unaffected mothers may be due to marked skewing of X inactivation, with preferential inactivation of the normal allele in the daughters and of the mutant allele in the mothers (Sybert 1989). It has also been suggested that the phenotype of affected individuals in

Received February 24, 1997; accepted for publication April 25, 1997.

Address for correspondence and reprints: Dr. Jonathan Zonana, Department of Molecular and Medical Genetics L-103, Oregon Health Sciences University, 3181 S.W. Sam Jackson Park Road, Portland, OR 97201. E-mail: zonana@ohsu.edu

© 1997 by The American Society of Human Genetics. All rights reserved.
0002-9297/97/6101-0015\$02.00

the putative autosomal recessive form of HED, including those reported by Passarge et al. (1966), is distinct from that seen in the X-linked form of the disorder (Anton-Lamprecht et al. 1988; Sybert 1989).

With the existence of molecular polymorphic markers that flank the *EDA* locus, one can test whether these markers cosegregate with the disorder in these rare families (Zonana et al. 1992; Zonana 1993). Five families with possible ARHED have been identified, on the basis of the presence of severely affected females and unaffected parents in a single sibship or in consanguineous families with affected family members in multiple sibships. The clinical features of the affected individuals were analyzed, as was the cosegregation of the disorder with molecular polymorphic markers flanking the *EDA* locus. The *EDA* gene was screened for mutations in families when affected individuals were found to share a common haplotype of flanking markers.

Subjects and Methods

Families Studied

Five families were studied, three from the United States, each containing a single affected sibship, and two consanguineous families from the United Arab Emirates and Israel, each having more than one affected sibship (fig. 1). After informed consent was obtained, blood was obtained for DNA isolation by standard methods (Miller and Dykes 1988). Clinical examinations were performed on all relevant family members, with careful attention to dentition, scalp hair, and patchiness of body-hair distribution. Sweat-pore analyses were not routinely performed.

ED 1176 (United Arab Emirates).—A 23-year-old female (VI-5) presented to a dermatologist with complaints of periorbital wrinkling and hyperpigmentation (fig. 2, *left*). Facial features were notable for sparse eyelashes and lateral portions of her eyebrows, with prominent lips and ears. Only 15 teeth were present, and the canines and incisors had a conical crown shape. Scalp hair was fine, and there was little body hair. Her skin was dry and smooth, with poorly developed dermatoglyphics, and her breasts were rudimentary, with hypoplastic nipples. She suffered from xerostomia, ozena, and recurrent epistaxis and had total absence of sweating, with marked heat intolerance. During her early childhood, she had multiple admissions for fever and convulsions. Her nails were normal, and she was of normal intelligence. The proband's 17-year-old sister (VI-9) (fig. 2, *right*) had identical clinical signs and symptoms, with multiple admissions for fever and convulsions. She had 13 teeth, 10 of which had a conical crown form. Both women had normal 46,XX karyotypes, and their parents had normal clinical examinations. Skin biopsies of the forearms and thenar region of the palms showed no evidence of sweat glands or hair-follicle for-

mation. The parents are first cousins, and the affected sisters have two unaffected brothers and five unaffected sisters. An additional branch of the family, also consanguineous, had two affected females and one affected male among nine siblings. These cousins are related to the proband through unaffected males and were unavailable for examination or blood sampling.

ED 1185 (Israel).—The proband (V-2) was hospitalized at 41 d of age, because of a fever (41.4°C) of unknown origin, and was last seen at 9.5 years of age. His facial features were marked by a saddle-shaped nose, protruding lips, sparse eyebrows and eyelashes, and periorbital wrinkling. Scalp hair was sparse and light colored, and body hair was absent. He had normal nails but only three teeth, two of them permanent dentition. He was of normal intelligence. He was from a consanguineous Arab family in Israel, and his parents were first cousins. He had an unaffected younger sister. The proband had a similarly affected male cousin (V-3). The mothers are related only through unaffected male predecessors. He was admitted for hyperthermia in excess of 41°C and had dysmorphic facial features similar to those of his cousin. He did not sweat and had sparse eyebrows, eyelashes, and body hair, with normal nails. At 8 years of age he had two permanent teeth and had an attention-deficit disorder. Another cousin (V-6), from a different sibship, was suspected of having ectodermal dysplasia as a neonate, on the basis of dry peeling skin, and an x-ray study showed no tooth buds. His eyebrows and eyelashes were sparse, with fine wrinkling around his eyes. All three males had a normal 46,XY karyotype, and their mothers had 46,XX karyotypes. Careful examination of the parents of each child showed no signs of ectodermal dysplasia.

ED 1124 (United States—Texas).—The proband (III-2) presented at 22 years of age, for evaluation of ectodermal dysplasia. She had absent eyelashes and scant eyebrows, dry skin with absent body hair, and periorbital wrinkling of the skin. She reported that she did not sweat and was heat intolerant. Nails were normal, but no information is available about her breast development. She had only two of her permanent dentition. Her 25-year-old brother (III-1) had an identical clinical picture; he did not sweat and had sparse scalp and body hair and periorbital wrinkling and hyperpigmentation. He has 20 of his permanent dentition. The parents are unaffected, and there is no known consanguinity.

ED 1014 (United States—Oregon).—The proband, a 3.5-year-old male (II-1), presented with heat intolerance due to lack of sweating, hypodontia with conical shaped tooth crowns (10 primary teeth), sparse blond scalp hair, periorbital wrinkling, and eczema (fig. 3, *left*). His 18-month-old sister (II-2) was equally affected, with abnormal sweating, hypodontia (two conical shaped teeth), sparse blond scalp hair, and eczema (fig. 3, *right*). She and her brother had normal nails and nipples. Their mother and

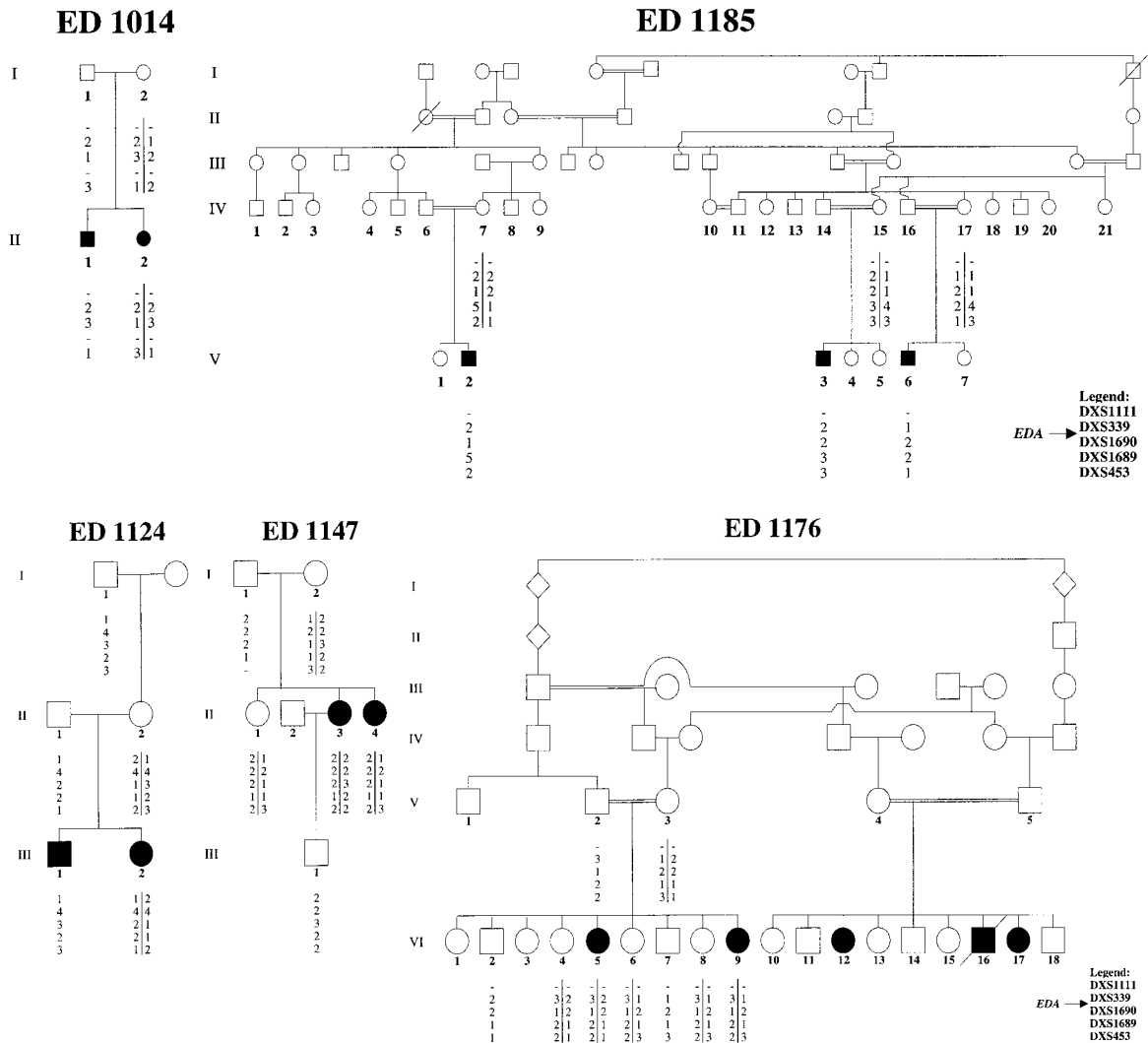


Figure 1 Pedigrees of families studied, with affected individuals indicated (*blackedened symbols*) and with haplotypes shown for marker loci flanking the *EDA* locus.

father had normal clinical examinations, without abnormalities of sweating, hair, or dentition. The parents are nonconsanguineous, and there are no other affected relatives. Follow-up examinations at ages 7 and 5 years, respectively, showed continued heat intolerance, with the brother having a total of 16 teeth (12 primary) and his sister having 10 primary teeth. The family was nonconsanguineous.

ED 1147 (United States—Washington State).—The clinical features of this family have been described elsewhere (Sybert 1989). Two females (II-3 and II-4) are affected in the sibship, one more severely than the other. One sister (II-3) presented with heat intolerance, delayed dental eruption, and scalp hair that was fine and sparse. She had no visible sweat pores on her fingertips and had only four permanent teeth. At 6 years of age, her younger sister (II-4) had 16 teeth, with small peg-shaped

incisors, did not have heat intolerance, and had patchy areas of sparse hair on her scalp. This sister had a decreased number of sweat pores, but both their mother and their unaffected sister had a normal sweat-pore count. The family was nonconsanguineous.

Molecular Methods

Five microsatellite (CA)_n markers from the Xq12-q13.1 region were utilized to construct haplotypes flanking the *EDA* locus for key individuals in the families (table 1). Sufficient markers were run in each family so that all families were informative for flanking markers. On the basis of our own and other studies, the order of the markers in the region is cen-DXS1111-DXS339-(*EDA*/DXS1690)-DXS1689-DXS453-tel (Browne et al. 1993; Zonana 1993; Fain et al. 1995; Weeks et al. 1995). No recombinants have been ob-

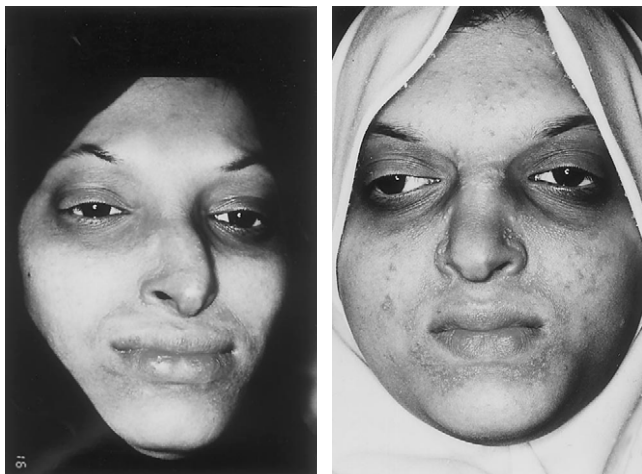

Figure 2 Affected sisters, one 23 years old (*left*) and one 17 years old (*right*), from a consanguineous family (ED 1176). Note the periorbital wrinkling and hyperpigmentation of the skin.

served between *EDA* and markers DXS339 and DXS1690. Marker DXS1690 is deleted in four males who have ectodermal dysplasia and submicroscopic molecular deletions (Kere et al. 1996). Only 1 recombinant in 241 informative meioses has been observed between DXS339 and DXS453 in the CEPH families (Fain et al. 1995). PCR amplification and scoring of the microsatellite alleles were performed by previously published methods referenced in table 1.

For SSCP analysis of the *EDA* gene, genomic DNA was amplified by PCR utilizing primers flanking exon 1, and the products were analyzed by previously published methods (Kere et al. 1996). Primers for exon 2 were designed from flanking genomic sequence. PCR was performed in a final volume of 20 μ l with a final concentration of 1 \times PCR buffer (Perkin Elmer), 3 mM MgCl₂,

0.2 mM dNTP, 0.5 mM forward primer (5'-TGGCTTCTCTAGTTAGGTTGGG-3'), 0.5 mM reverse primer (5'-CATCTCAAATTTTCCTTCTGGG-3'), 0.05 U *Taq* DNA polymerase (Perkin Elmer)/ μ l, and 2.5 ng genomic DNA/ μ l. The mix (without dNTPs) was overlaid with 20 μ l mineral oil and then was "hot-started" with the dNTP mix. The PCR program consisted of an initial denaturation step at 95°C for 2 min 30 s, followed by 30 cycles of denaturation at 94°C for 30 s, annealing at 60°C for 30 s, and extension at 72°C for 30s, with a final extension step at 72°C for 5 min. The expected product size for exon 2 was 372 bp. Five microliters of the PCR product was digested in a final volume of 10 μ l with 5 U *Tru9I*, generating fragments of 84, 151, and 157 bp. Digests were denatured at 95°C for 10 min, chilled on ice, electrophoresed on a 0.5 \times HydroLink™ gel (J. T. Baker) run at 1 W/cm for 3 h at room temperature, and visualized by silver staining.

Results

Clinical Findings

Males and females are equally affected in the families examined, as seen in families ED 1014 and 1176. The clinical findings and degree of involvement of the teeth, sweat glands, and hair were indistinguishable from those of males affected with X-linked HED (table 2 and figs. 2 and 3). The only exception to this was family ED1147, in which one of the sisters was less severely affected. All parents of affected individuals were clinically normal.

Molecular Analyses

All families were informative for one or more markers that closely flank the *EDA* locus, and the results of the haplotypes are shown in figure 1. In four of the five

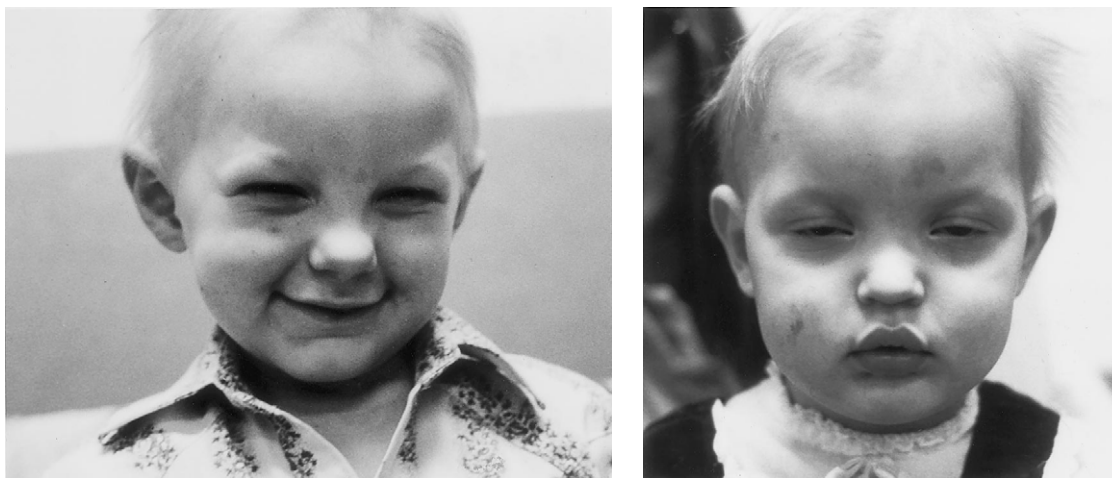

Figure 3 Two siblings, a 3.5-year-old male (*left*) and his 18-mo-old sister (*right*), from family ED 1014. Note their equal severity of involvement, including sparse scalp hair and periorbital pigmentation and wrinkling.

Table 1**Markers Utilized**

Marker	Heterozygosity	Primer Name	Primer Sequence	Reference
DXS1111	.79	{ A0353/A A0352/B	{ 5'-AATGACCTTTTTCCTGGAGAC-3' 5'-TCCCATACCTCACTCAGGCTT-3' }	Browne et al. (1993)
DXS339	.73	{ DXS339F DXS339R	{ 5'-ATGAAATAGCCCAGTACTCC-3' 5'-TCTGCTATAACCCACCCATC-3' }	Zonana et al. (1992)
DXS1690	.83	{ NIMG7a NIMG7b	{ 5'-AGACTGGATTTGTACGATGC-3' 5'-GGACAGAAAGATGATAAGGG-3' }	Weeks et al. (1995)
DXS1689	.72	{ NIMG9a NIMG9b	{ 5'-TAAACTAAAAAGAGGTGTGCG-3' 5'-CCTTAGCCACTGAGTTTGTTC-3' }	Weeks et al. (1995)
DXS453	.68	{ Mfd66GT Mfd66CA	{ 5'-AACCTCAGCTTATACCCAAG-3' 5'-GCCCTACCTTGGCTAGTTA-3' }	Zonana et al. (1992)

families, the affected siblings and relatives did not share a common haplotype inherited from their mothers, as would be expected in an X-linked disorder when the father is unaffected. In family ED1147, the two affected sisters, as expected, share a common haplotype from their unaffected father, and thus gonadal mosaicism in the father cannot be formally excluded. None of three affected males in family ED1185 shared a common haplotype. In ED 1176, the two affected sisters (VI-5 and VI-9) inherited different haplotypes from their mother, as did the two unaffected brothers (VI-2 and VI-7). The affected brother and sister in ED 1124 have different maternally derived haplotypes, whereas the affected brother and sister in family ED1014 share the same maternal EDA haplotype inherited from their unaffected mother. The latter may occur with a 50% probability even if the disorder is not linked to the

EDA locus. Since the affected individuals in ED 1014 and ED 1147 shared haplotypes flanking the EDA gene, the gene was screened, by SSCP, for mutation analysis; none were found.

Discussion

In 1966, Passarge et al. reported a highly inbred kindred with three sisters and three first cousins, including two males, with full manifestations of HED and suggested autosomal recessive inheritance. Other authors both prior and subsequent to this report suggested the existence of this rare autosomal recessive form of HED (Gorlin et al. 1970; Crump and Danks 1971). Sybert (1989) questioned whether there was sufficient evidence to establish an autosomal recessive form of the disorder and suggested that molecular diagnostic techniques might resolve the issue.

Table 2**Clinical Findings**

	FAMILY ED 1014		FAMILY ED 1124		FAMILY ED 1147		FAMILY ED 1176		FAMILY ED 1185		
	II-1 M	II-2 F	III-2 F	III-1 M	II-3 F	II-4 F	VI-5 F	VI-9 F	V-2 M	V-3 M	V-6 M
Decreased sweating	+	+	+	+	+	+	+	+	?	+	+
Hypodontia	+	+	+	+	+	+	+	+	+	+	+
Conical teeth	+	+	+	+	+	+	+	+	NA	+	+
Hypotrichosis of the scalp	+	+	+	+	+	+	+	+	NA	+	+
Sparse or absent eyebrows and eyelashes	+	+	+	+	+	+	+	+	NA	+	+
Sparse or absent body hair	+	+	+	+	+	+	+	+	NA	?	+
Dry skin or eczema	+	+	+	+	+	-	-	-	+	+	+
Hypoplastic nails	-	-	-	-	-	-	-	-	-	-	-
Hypoplastic breasts	NA	NA	?	NA	-	+	+	+	NA	NA	NA
Atrophic rhinitis and ozena	+	+	?	?	+	-	+	+	?	?	?
Depressed nasal bridge	+	+	+	+	+	+	+	+	?	+	+
Hyperpigmented and wrinkled periorbital skin	+	+	+	+	+	+	+	+	?	?	+

NOTE.—A plus sign (+) denotes presence; a minus sign (-) denotes absence; ? = no information; and NA = not applicable.

The failure of the disorder to cosegregate with markers closely flanking the *EDA* locus excludes the disorder from the *EDA* locus in three of the families (ED 1124, ED 1176, and ED 1185) reported here. The probability of an event such as double recombination between the flanking loci, or gene conversion, is extremely small. The presence of equally affected males and females and unaffected parents argues against an X-linked recessive trait and supports autosomal recessive inheritance. The consanguinity seen in two families (ED1176 and ED1185) with more than one affected sibship, as well as reports of other consanguineous families (Sybert 1989), further supports autosomal recessive inheritance. In the two families in which there was a shared haplotype in the *EDA* region, no mutations were detected by SSCP analysis. Currently, only 10% of mutations can be detected in families with X-linked HED (Ferguson et al. 1996). Therefore, at the present time, direct mutation analysis is not useful in distinguishing ARHED from X-linked HED.

The clinical appearance of affected males and females with ARHED is indistinguishable from that of males affected with X-linked HED and from that in females with balanced X; autosome translocations involving the *EDA* locus. Any fully affected female should be karyotyped, to rule out an X; autosome translocation. ARHED would be suggested if the karyotype is normal, the parents are determined to be unaffected after careful physical examination, and either only a single sibship is affected or there is consanguinity. In the case of either a sporadic affected male or affected male siblings with no family history, one cannot distinguish X-linked HED from ARHED. The X-linked form of the disorder is many times more common than the autosomal forms, but an exact frequency of each is unknown. Only either improvement in direct mutation analysis of the *EDA* gene or the isolation of the gene(s) responsible for ARHED will help in distinguishing between these disorders.

The human *EDA* locus appears to be homologous to the mouse *Tabby* locus, both displaying abnormal morphogenesis of ectodermal derivatives, as well as mapping to syntenic regions on the X chromosome (Blecher 1986). Two autosomal recessive loci (*dl* and *cr*) that exist in the mouse are, when mutant, indistinguishable from the phenotype of the *Tabby* mouse (Sofaer 1974; Sofaer 1979). It is likely that the *cr* and *dl* loci in the mouse are homologous to the locus or loci involved in human ARHED. The *cr* and *dl* loci have been mapped in the mouse, but there are no obvious candidate genes either near their locations or in the human syntenic regions. The gene products of these X-linked and autosomal loci, in both mouse and humans, are likely critical components of a common developmental pathway in the morphogenesis of hair, teeth, eccrine sweat glands, and mammary tissue.

Acknowledgments

This work was supported by National Institute of Dental Research grant RO1-DE11311-6 and by a National Foundation for Ectodermal Dysplasias grant.

References

- Anton-Lamprecht I, Schleiermacher E, Wolf M (1988) Autosomal recessive anhidrotic ectodermal dysplasia: report of a case and discrimination of diagnostic features. *Birth Defects* 24:183–195
- Blecher SR (1986) Anhidrosis and absence of sweat glands in mice hemizygous for the *Tabby* gene: supportive evidence for the hypothesis of homology between *Tabby* and human anhidrotic (hypohidrotic) ectodermal dysplasia (Christ-Siemens-Touraine syndrome). *J Invest Dermatol* 87:720–722
- Browne DL, McMilin KD, Litt M (1993) Dinucleotide repeat polymorphism at the *DXS1111* locus. *Hum Mol Genet* 2:611
- Clarke A, Phillips DI, Brown R, Harper PS (1987) Clinical aspects of X-linked hypohidrotic ectodermal dysplasia. *Arch Dis Child* 62:989–996
- Crump IA, Danks DM (1971) Hypohidrotic ectodermal dysplasia: a study of sweat pores in the X-linked form and in a family with probable autosomal recessive inheritance. *J Pediatr* 78:466–473
- Fain PR, Kort EN, Chance PF, Nguyen K, Redd DF, Econs MJ, Barker DF (1995) A 2D crossover-based map of the human X chromosome as a model for map integration. *Nat Genet* 9:261–266
- Ferguson BM, Munoz F, Kere J, Srivastava AK, Zonana J (1996) Diagnostic utility of direct mutation analysis in X-linked hypohidrotic ectodermal dysplasia. *Am J Hum Genet Suppl* 59:A258
- Freire-Maia N, Pinheiro M (1982) Carrier detection in Christ-Siemens-Touraine syndrome (X-linked hypohidrotic ectodermal dysplasia). *Am J Hum Genet* 34:672–674
- Gorlin RJ, Old T, Anderson VE (1970) Hypohidrotic ectodermal dysplasia in females: a critical analysis and argument for genetic heterogeneity. *Z Kinderheilkd* 108:1–11
- Kere J, Srivastava AK, Montonen O, Zonana J, Thomas N, Ferguson B, Munoz F, et al (1996) X-linked anhidrotic (hypohidrotic) ectodermal dysplasia is caused by mutation in a novel transmembrane protein. *Nat Genet* 13:409–416
- Kiss P, Torok E (1990) Autosomal recessive inheritance of hypohidrotic ectodermal dysplasia. *Pediatr Dermatol* 7:242
- Limon J, Filipiuk J, Nedoszytko B, Mrozek K, Castren M, Larramendy M, Roszkiewicz J (1991) X-linked anhidrotic ectodermal dysplasia and de novo t(X;1) in a female. *Hum Genet* 87:338–340
- MacDermot KD, Hulten M (1990) Female with hypohidrotic ectodermal dysplasia and de novo (X;9) translocation: clinical documentation of the AnLy cell line case. *Hum Genet* 84:577–579
- Miller SA, Dykes DD (1988) A simple salting out procedure for extracting DNA from human nucleated cells. *Nucleic Acids Res* 16:1215
- Parant M, Cayron R, Ragot CM, Boubilil (1969) Anodontia as part of an ectodermal dysplasia with anhidrosis and hypotrichosis. *Rev Stomatol Chir Maxillofac* 70:461–470

- Passarge E, Nuzum CT, Schubert WK (1966) Anhidrotic ectodermal dysplasia as autosomal recessive trait in an inbred kindred. *Humangenetik* 3:181–185
- Plougastel B, Couillin P, Blanquet V, Le Guern E, Bakker E, Turleau C, De Grouchy J, et al (1992) Mapping around the Xq13.1 breakpoints of two X/A translocations in hypohidrotic ectodermal dysplasia (EDA) female patients. *Genomics* 14:523–525
- Sofaer JA (1974) Differences between tabby and downless mouse epidermis and dermis in culture. *Genet Res* 23:219–225
- (1979) Additive effects of the genes tabby and crinkled on tooth size in the mouse. *Genet Res* 33:169–174
- Sybert VP (1989) Hypohidrotic ectodermal dysplasia: argument against an autosomal recessive form clinically indistinguishable from X-linked hypohidrotic ectodermal dysplasia (Christ-Siemens-Touraine syndrome). *Pediatr Dermatol* 6:76–81
- Turleau C, Niaudet P, Cabanis MO, Plessis G, Cau D, de Grouchy J (1989) X-linked hypohidrotic ectodermal dysplasia and t(X;12) in a female. *Clin Genet* 35:462–466
- Weeks DE, Nygaard TG, Neystat M, Harby LD, Wilhelmsen KC (1995) A high-resolution genetic linkage map of the pericentromeric region of the human X chromosome. *Genomics* 26:39–46
- Zonana J (1993) Hypohidrotic (anhidrotic) ectodermal dysplasia: molecular genetic research and its clinical applications. *Semin Dermatol* 12:241–246
- Zonana J, Jones M, Browne D, Litt M, Kramer P, Becker HW, Brockdorff N, et al (1992) High-resolution mapping of the X-linked hypohidrotic ectodermal dysplasia (EDA) locus. *Am J Hum Genet* 51:1036–1046